



Case Report

DOI: 10.64951/jmdnt.2025.1.1

## Management of a Complex Craniofacial Injury Following a Self-Inflicted Gunshot Wound

Ayhan Yildirim <sup>a\*</sup>, René Hertach <sup>b</sup>, Vedat Yildirim <sup>b</sup>

<sup>a</sup> Hochschule Zurich, Department of Medicine, Zurich, Switzerland

<sup>b</sup> Hochschule Zurich, Department of Dentistry, Zurich, Switzerland

### ARTICLE INFO

#### **Article history:**

Received 15 October 2024,

Revised 25 February 2025,

Accepted 04 April 2025,

Available online 22 April 2025,

Version of Record 22 April 2025.

#### **Keywords:**

Gunshot wound to the head (GSHW);

Suicide;

Interdisciplinary management;

Facial trauma;

Ethics.

### ABSTRACT

Suicide attempts are tragic and complex events that often require immediate and interdisciplinary treatment to achieve the best possible outcome.

We present the case of a 57-year-old male who attempted suicide with an assault rifle in the presence of his family. He had a long history of depression and had discontinued his prescribed antidepressant medication. Following a family conflict, he attempted suicide by firing a shot that entered the submental region, shattered the mandible, bypassed the maxilla, destroyed most of the nasal and frontonasal structures, and exited through the frontal lobe and frontal bone. Such cases are rare in current medical practice. We describe the acute and interdisciplinary management of this severe craniofacial injury caused by a self-inflicted gunshot wound.

\* Corresponding author. Hochschule Zurich, Albisstrasse 80, 8038 Zurich, Switzerland  
E-mail address: [ayhan.yildirim@uni-zh.ch](mailto:ayhan.yildirim@uni-zh.ch).

Peer review under responsibility of Hochschule Zurich.

<https://jmdnt.com/issue-2025-1-article-1/>

DOI: 10.64951/jmdnt.2025.1.1 / Hochschule Zurich, Publishing services by Journal of Medicine and Dentistry. This is an open access article

## At a glance commentary

### *Scientific background on the subject*

Self-inflicted gunshot injuries to the head are rare but often fatal. Advances in trauma surgery, neurocritical care, and interdisciplinary management have improved survival in selected patients, yet the literature on complex craniofacial injuries caused by high-velocity assault rifles remains limited. What this study adds to the field

### *What this study adds to the field*

This case demonstrates that rapid, coordinated intervention by an interdisciplinary team—including neurosurgery, maxillofacial surgery, anesthesiology, and ophthalmology—can achieve survival and functional preservation even after devastating bifrontal gunshot trauma. The report highlights surgical strategies for skull base reconstruction and addresses the ethical challenges of aggressive care in self-inflicted injuries.

## INTRODUCTION

Worldwide, more than 720,000 people die by suicide each year, according to the World Health Organization (WHO). This corresponds to approximately one death every 43 seconds. In 2019, suicide was estimated to account for 1.3% of the total global burden of disease. Mental disorders—particularly depression, alcohol abuse, and other addictive disorders—are major risk factors for suicide in Europe and North America. In many Asian countries, impulsiveness also plays an important role. Suicide is a multifactorial phenomenon influenced by psychological, social, biological, cultural, and environmental factors [1]. Assault rifles are high-velocity weapons that cause devastating tissue destruction due to the tremendous energy transfer upon impact. When used on the facial skeleton, the resulting injuries are typically catastrophic.

## Map of International Suicide Rates:

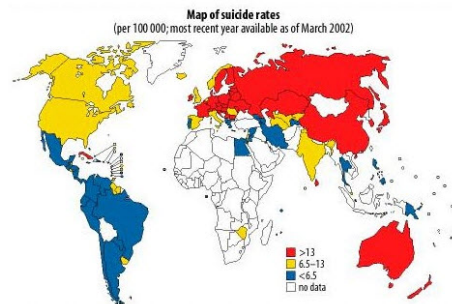


Figure 1: map of international suicide rates from

## Case Report

### Background

The patient had experienced chronic professional overload for years, which had worsened in recent weeks. He consumed approximately 1 liter of wine and 1–2 packs of cigarettes daily. According to his wife, he had shown signs of neglecting personal hygiene and a marked loss of interest in daily activities. He had been prescribed antidepressants but discontinued the medication after a short period.

### Initial Presentation

A 57-year-old man was airlifted to the emergency room of the Seeklinik Zurich, a specialist clinic for oral, maxillofacial, and plastic facial surgery in critical condition after a self-inflicted gunshot wound to the face with an assault rifle. He had not been intubated at the scene but was transported in the prone position due to a compromised airway and the severity of his injuries. His Glasgow Coma Scale (GCS) score was 12 on arrival. He was heavily sedated (blood alcohol level 56.8 mmol/L  $\approx$  2.6 ‰), precluding a full neurological assessment.

Clinical examination suggested that the bullet had entered the submental region, split the lower lip, comminuted the mandible, passed superiorly without damaging the maxilla, and exited through the frontal bone, causing massive destruction of the nasal and frontal areas and injury to the frontal lobe.

Bleeding was surprisingly minimal and controlled with compression bandages. A corneal perforation with complete loss of intraocular contents of the left eye was noted.

Despite the extensive injuries, the patient retained the ability to move all extremities and utter a few isolated words. To protect the airway, he was orally intubated and underwent immediate diagnostic imaging.

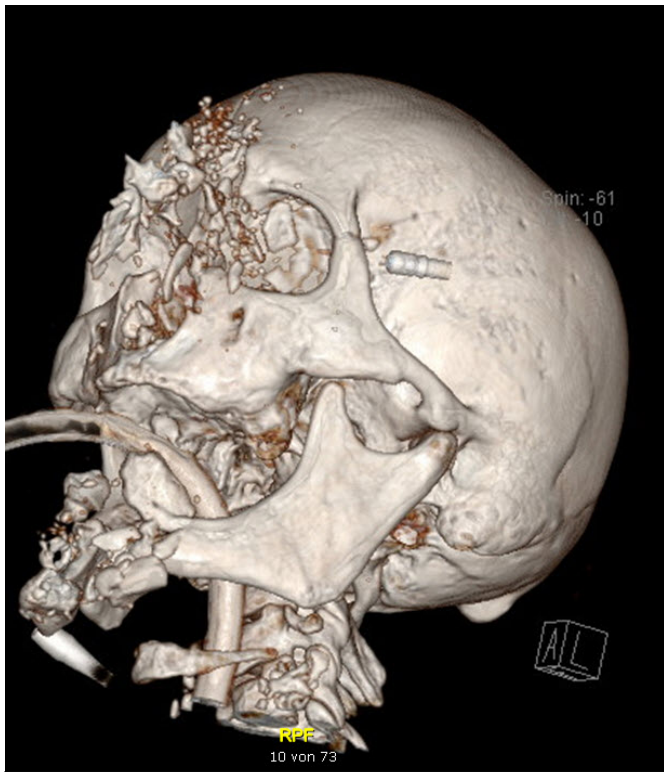


Figure 2: initial situation

Computed tomography revealed comminution of the frontal skull base with interhemispheric distribution of bone fragments, bifrontal cerebral hemorrhage with pneumocephalus extending to the vertex, complex midface fractures, comminution of both orbits, and numerous bone fragments along the bullet trajectory. The nasal bones and septum were completely destroyed and displaced. Multiple mandibular fractures with bone loss were present, and the left eye contained no residual intraocular structures. Due to intracranial injuries, intravenous prophylaxis with ceftriaxone (Rocephin®) was initiated.

After discussion with the family, life-supportive and interventional care was pursued.

### Management

An interdisciplinary team consisting of emergency surgeons, anesthesiologists, neurosurgeons, and maxillofacial surgeons was assembled.

The patient was transferred to the operating theater, where a tracheotomy was performed. Neurosurgeons conducted a frontobasal craniotomy, debridement, and reconstruction using a large vascularized pericranial flap based on the left supraorbital vessels. Because closure of the dural defect remained challenging and significant dead space persisted, bilateral transverse temporal muscle flaps were sutured in the midline by the maxillofacial team. Due to the absence of brain swelling and the patient's initially stable condition, the team decided not to place an intracranial pressure catheter.

The maxillofacial surgeons performed conservative debridement, preserving all viable bone fragments. Using miniplates and titanium mesh, both medial orbital rims and walls were reconstructed, and both lacrimal canals were splinted with silicone tubes. The mandible was stabilized with miniplates and lag screws; a reconstruction plate bridged the defect and served as a base for reattaching fragments. Soft tissues were carefully closed, excising only clearly necrotic skin and mucosa. Significant soft-tissue deficits remained in the frontal and frontonasal regions.

Once the extent of the ocular injury became evident, ophthalmologists performed evisceration of the left eye with placement of a silicone implant and temporary tarsorrhaphy. Postoperatively, persistent cerebrospinal fluid leakage was observed from the frontal defect. Three days later, at the request of the neurosurgeons, the residual dural and frontonasal soft-tissue defect was covered using a radial forearm free flap.

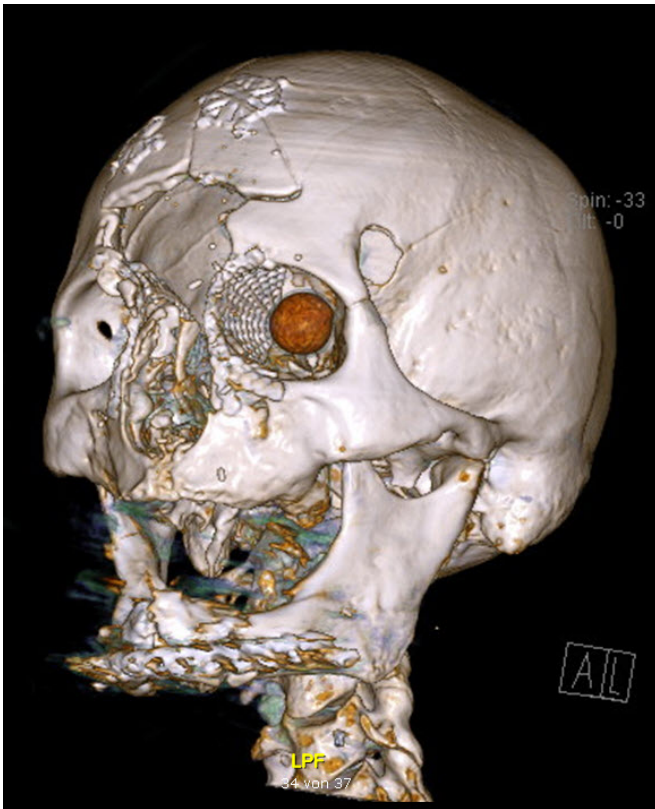


Figure 3: Check-up after 6 months

## DISCUSSION

Reported mortality rates for suicide attempts with gunshot wounds to the head range from 7.7% to 93% [2–14]. In this case, the patient survived an extensive emergency operation performed by an interdisciplinary team. Between 1990 and 2008, Loyola V. Gressot et al. reported 199 cases of suicide-related gunshot wounds to the head admitted to Ben Taub General Hospital, a Level I trauma center. Among those who survived initial resuscitation, 19% of all patients—and 40% of those who survived the first phase—ultimately achieved a favorable functional outcome at 6-month follow-up. Gressot et al. proposed a scoring system for the rapid assessment of GSWH patients based on GCS score on admission, age, pupillary reactivity, and bullet trajectory [3].

### GCS Score

Our patient had an initial GCS of 12, increasing to 13 in the shock room, which was prognostically favorable. Lower GCS scores are associated with higher mortality and worse functional outcomes [4, 5, 7–9, 11, 13, 15, 16].

In cases with ocular injury, tongue trauma, or nerve damage, however, GCS assessment may be limited. Grahm et al. and Martins et al. suggested that aggressive surgical intervention should only be considered in patients with a GCS of at least 3–5 [17].

### Age and Sex

The patient was a 57-year-old male. Gressot et al. found that most suicide patients are between 20 and 40 years old [8]. Older age is associated with worse outcomes [13, 15]. Kaufman et al. observed that women generally have better survival rates, possibly because they are less likely to use firearms [15].

### Pupils

Bilaterally nonreactive pupils are a negative prognostic indicator [14, 15, 18]. In this case, the left pupil was destroyed, and the right pupil was 3 mm, slightly oval, and sluggishly reactive to light. Assessment was challenging due to bleeding. Some authors caution that pupillary response is unreliable in patients with very low GCS scores [4]. Pupil reactivity appears most predictive in patients with GCS scores of 3–5 [19].

### Bullet Trajectory

The bullet in this case destroyed the frontal area and injured the frontal lobe. Trajectory significantly influences mortality and morbidity, with bihemispheric and posterior fossa injuries associated with worse outcomes [4, 5, 7–9, 11–13, 15, 16, 18]. Martins et al. reported mortality rates of 96.2% for bihemispheric injuries and 100% for posterior fossa injuries [8]. In contrast, Nathoo et al. reported a mortality rate of only 19.2% in a cohort with higher mean GCS scores ( $\geq 6$ ) [10]. Patients with isolated bifrontal injuries, such as in this case, may have outcomes similar to those with unihemispheric injuries [14].

### Other Factors

Associated injuries, respiratory arrest, and hypotension on arrival have been linked to higher mortality [5, 15, 20]. On admission, the patient had a blood pressure of 70/30 mm Hg, a heart rate of 161 bpm, oxygen saturation of 83%, respiratory rate of 12, and a core temperature of 35.4 °C.

Ethical considerations are critical in treating self-inflicted injuries. While suicide attempts may represent a patient's autonomous decision, they often signal a desperate cry for help. Physicians must balance respect for patient autonomy with the ethical imperative to preserve life, ideally in consultation with family members and psychiatric specialists.

### Conclusion

Gunshot wounds to the brain remain a major challenge for clinicians due to their high mortality and poor neurological outcomes. We report the survival of a patient with a self-inflicted bifrontal gunshot injury, discussing key prognostic factors including GCS score, age, pupillary response, and bullet trajectory. Despite the often grim prognosis, every patient should receive the best possible medical care, independent of initial clinical scoring.

### Ethics statement

This case report was conducted in Hochschule Zurich, under the approval of the Institutional Review Board (IRB) of Hochschule Zurich. Written informed consents were obtained from the patient.

### Conflicts of interest

The authors have no financial conflicts of interest.

### References

- [1] Shah, A., et al., Suicide in centenarians: the international landscape. *Int Psychogeriatr*, 2014: p. 1-6.
- [2] Benzel, E.C., et al., Civilian craniocerebral gunshot wounds. *Neurosurgery*, 1991. 29(1): p. 67-71; discussion 71-2.
- [3] Cavaliere, R., et al., Gunshot wounds of the brain in civilians. *Acta Neurochir (Wien)*, 1988. 94(3-4): p. 133-6.
- [4] Grahm, T.W., et al., Civilian gunshot wounds to the head: a prospective study. *Neurosurgery*, 1990. 27(5): p. 696-700; discussion 700.

- [5] Jacobs, D.G., et al., Transcranial gunshot wounds: cost and consequences. *Am Surg*, 1995. 61(8): p. 647-53; discussion 653-4.
- [6] Kaufman, H.H., Civilian gunshot wounds to the head. *Neurosurgery*, 1993. 32(6): p. 962-4; discussion 964.
- [7] Kim, T.W., et al., Penetrating gunshot injuries to the brain. *J Trauma*, 2007. 62(6): p. 1446-51.
- [8] Martins, R.S., et al., Prognostic factors and treatment of penetrating gunshot wounds to the head. *Surg Neurol*, 2003. 60(2): p. 98-104; discussion 104.
- [9] Nagib, M.G., et al., Civilian gunshot wounds to the brain: prognosis and management. *Neurosurgery*, 1986. 18(5): p. 533-7.
- [10] Nathoo, N., et al., Civilian infratentorial gunshot injuries: outcome analysis of 26 patients. *Surg Neurol*, 2002. 58(3-4): p. 225-32; discussion 232-3.
- [11] Ozkan, U., et al., Analysis of 107 civilian craniocerebral gunshot wounds. *Neurosurg Rev*, 2002. 25(4): p. 231-6.
- [12] Shoung, H.M., J.P. Sichez, and B. Pertuiset, The early prognosis of craniocerebral gunshot wounds in civilian practice as an aid to the choice of treatment. A series of 56 cases studied by the computerized tomography. *Acta Neurochir (Wien)*, 1985. 74(1-2): p. 27-30.
- [13] Siccardi, D., et al., Penetrating craniocerebral missile injuries in civilians: a retrospective analysis of 314 cases. *Surg Neurol*, 1991. 35(6): p. 455-60.
- [14] Stone, J.L., T. Lichtor, and L.F. Fitzgerald, Gunshot wounds to the head in civilian practice. *Neurosurgery*, 1995. 37(6): p. 1104-10; discussion 1110-2.
- [15] Kaufman, H.H., et al., Gunshot wounds to the head: a perspective. *Neurosurgery*, 1986. 18(6): p. 689-95.
- [16] Khan, M.B., et al., Civilian Craniocerebral Gunshot Injuries in a Developing Country: Presentation, Injury Characteristics, Prognostic Indicators, and Complications. *World Neurosurg*, 2013.
- [17] Clark, W.C., et al., Analysis of 76 civilian craniocerebral gunshot wounds. *J Neurosurg*, 1986. 65(1): p. 9-14.

- 
- [18] Levy, M.L., Outcome prediction following penetrating craniocerebral injury in a civilian population: aggressive surgical management in patients with admission Glasgow Coma Scale scores of 6 to 15. *Neurosurg Focus*, 2000. 8(1): p. e2.
- [19] Levy, M.L., et al., Outcome prediction after penetrating craniocerebral injury in a civilian population: aggressive surgical management in patients with admission Glasgow Coma Scale scores of 3, 4, or 5. *Neurosurgery*, 1994. 35(1): p. 77-84; discussion 84-5.
- [20] Murano, T., et al., Civilian craniocerebral gunshot wounds: an update in predicting outcomes. *Am Surg*, 2005. 71(12): p. 1009-14.
- [21] Turina, D., et al., War head injury score: an outcome prediction model in War casualties with acute penetrating head injury. *Mil Med*, 2001. 166(4): p. 331-4.